

RESEARCH

Clinical application of cone beam digital volume tomography in children with cleft lip and palate

R Wörtche^{*1}, S Hassfeld¹, CJ Lux², E Müssig², FW Hensley³, R Krempien³ and C Hofele¹

¹Department of Oral and Maxillofacial Surgery, University of Heidelberg, Im Neuenheimer Feld 400, 69120 Heidelberg, Germany;

²Department of Orthodontics, University of Heidelberg, Im Neuenheimer Feld 400, 69120 Heidelberg, Germany; ³Department of Radiation Oncology, University of Heidelberg, Im Neuenheimer Feld 400, 69120 Heidelberg, Germany

Objectives: The diagnostic advantages of digital volume tomography (DVT) over conventional imaging and computed tomography are demonstrated in terms of the respective radiation exposure. The potential role for three-dimensional imaging in cleft lip and palate patients is illustrated on the basis of clinical examples.

Methods: The radiation exposure resulting from scans using a cone beam DVT (NEW TOM QR-DVT 9000, Marburg, Germany) was measured with an Alderson-Rando-Phantom (The Phantom Laboratory, New York, NY) and compared with that resulting from other standard imaging modalities. The patient sample consisted of young children with cleft lip and palate on whom orthodontic and surgical treatment was planned on an interdisciplinary basis at the University-Hospital of Heidelberg.

Results: Digital volume tomography allows high-quality three-dimensional imaging of the premaxilla region, with an effective equivalent investigation dose of (110 kV, 5.4 mA) 0.342 mSv based on ICRP recommendations. While the effective equivalent investigation dose for DVT is higher than that for standard imaging techniques (for example digital panoramic radiograph Orthophos Plus DS Ceph (66 kV, 8 mA) 0.016 mSv), it is much lower than that for a normal CT scan (*e.g.* Picker International Inc., Highland Heights, OH) adjusted at (spiral 130 kV, 125 mA, and 30 mA, 1.5 s) 2.27 mSv. Digital volume tomography provides extensive data important in clinical decision making.

Conclusions: The clinical examples show the good applicability of DVT with a reduced radiation dose.

Dentomaxillofacial Radiology (2006) 35, 88–94. doi: 10.1259/dmfr/27536604

Keywords: digital volume tomography; computed tomography; 3D imaging; radiation dose; children; cleft lip palate

Introduction

Three-dimensional imaging techniques are increasing in importance compared with conventional radiological imaging techniques not only in routine diagnostics of head and neck, but also in parts of the body which require particular care in terms of radiation hygiene.^{1–3} Special attention must therefore be paid to limiting radiation exposure especially in younger patients, *e.g.* those with cleft lip and palate. This runs counter to the objective of obtaining detailed imaging of the osseous cleft region, the teeth and the tooth germs especially in orthodontic planning and surgical operations such as osteoplasty.^{4–6} Considerations in regard to the number of

teeth present, their three-dimensional orientation, prognosis of the teeth, bone quality and the amount of bone available arise constantly in everyday routine. Generally in patients presenting with cleft lip and palate conventional two-dimensional radiographic imaging such as panoramic and plain projections, particularly the cephalometric radiograph, are routinely used in oral and maxillofacial surgery and orthodontic treatment planning. Three-dimensional imaging of the defect has so far only been attained by computed tomography (CT), but in young patients the radiation exposure entailed is only justifiable in special cases.⁷

Since 1997, digital volume tomography (DVT) has been available as a commercial imaging technique. In principle, it provides the same three-dimensional imaging features as those afforded by CT, but with less dose per imaging study for the patient.⁸ For the present report we have routinely

*Correspondence to: Dr R Wörtche, Department of Oral and Maxillofacial Surgery, University of Heidelberg, Im Neuenheimer Feld 400, 69120 Heidelberg, Germany; E-mail: woertche@gmx.de

Received 8 September 2004; revised 19 May 2005; accepted 29 June 2005

used a digital volume tomograph (NEW TOM model QR-DVT 9000; New Tom, Marburg, Germany). The instrument has an X-ray tube that can be rotated by 360° with a maximum output of 110 kV and 10 mA. The tube functions in the range of moderately hard X-rays with a filtration of 0.7 mm Al and a constant 14° cone beam angle.⁹ The detector consists of an image intensifier (Thomson Tubes Electroniques, Moirans, France) with an 8 inch × 8 inch input window and an intensification factor of 22:1. The images are recorded with a charged coupled device (CCD) (Sony Corporation, Tokyo, Japan) chip with a matrix of 752 × 582 pixels. The raw data set comprising 94 MB is processed using the NEW TOM 9000 Dental reconstruction software operating under Windows NT (Microsoft Corporation, Redmond, WA). In generating the raw data set, the X-ray tube and the image intensifier revolve once by 360° around the stationary patient, a single projection image being taken per degree. In one 76 s cycle, a field of view with a rotation-symmetric volume 10 cm in height and 12 cm in diameter is scanned with an exposure time of 18 s. Based on the findings of a pre-scan, the 360 images are adjusted individually with the lowest possible scan dose using the smart beam technique to achieve a maximum dose reduction. After scanning, the initial data set is converted into a lateral planning tomogram in which the thickness of the axial layers to be reconstructed (0.3 mm; 1.0 mm; 3.0 mm) as well as the angle of reconstruction are determined.¹⁰ After primary reconstruction, further secondary reconstructions can be generated. These include sagittal, coronal, and para-axial sections as well as three-dimensional reconstruction.

The aims of the study were to categorise the radiation exposure of DVT in comparison with conventional and CT images, and to show the diagnostic importance of DVT in cleft diagnostics by means of clinical examples.

Materials and methods

Measurement of radiation exposure

This study compared the following imaging devices: digital volume tomograph NEW TOM (Model QR-DVT

9000; New Tom), adjusted at 110 kV, 5.4 mA (automatic dose pre-selection); Orthophos Plus DS Ceph (Sirona, Bensheim, Germany) (66 kV, 8 mA panoramic and 84 kV, 13 mA lateral head films, digital sensor); conventional orthopantomography device Orthophos Plus (66 kV, 16 mA) (Sirona); X-ray unit consisting of Vertix2/2FA and ceiling stand 3D III (Siemens, Erlangen, Germany) (77 kV, 18.4 mA); CT PQ-2000 device (Picker International Inc., Highland Heights, OH) adjusted at spiral 130 kV, 125 mA, and 30 mA, 1.5 s; CT device SOMATOM Volume Zoom (Siemens) adjusted at 120 kV, 42 mA, 1 mm. The parameters for the Picker CT investigation (reduction of the mAs product) were chosen on the basis of preliminary studies.¹¹

Lateral head films and occipito-frontal scan images were obtained with the usual positioning and insert (Vertix2/2FA and the ceiling stand 3D III; Siemens). One hundred exposures were performed with the panoramic, 25 with the DVT and 2 with the CT device. Average dose values were evaluated only when the measured values were consistent.

For measuring, an Alderson-Rando-Skull Phantom was equipped with thermoluminescence dosimeters (LiF-TLD; 6 mm × 1.5 mm × 1.5 mm) (TLD-100; Harshaw Chemical Company, Edison, NJ) according to the instructions of the manufacturer.

The respective positions in the phantom are shown in Table 1. They were each equipped with two TLD rods. For all measurements, the two identical rods were used in the same measuring positions. Upon analysis, the average value for each pair was evaluated. During each measurement, an additional group of 12 TLDs was irradiated with a dose of 1 Gy and also evaluated in the same cycle. A “regenerative correction factor” was calculated from the median deviation from 1 Gy in the results of the measurements of this reference group, and applied to the other dose measurements. This factor corrects for deviating conditions in the measuring cycle, such as electronic drifts or changes in the light-collecting properties of the measuring device. During each measurement, an empty measurement was determined from four non-irradiated TLDs and subtracted from the measurements of the irradiated TLDs.

Table 1 Weighted equivalent dose from two measurement cycles in mSv at the measured localizations in the Alderson-Rando-Phantom

	<i>Pan (Dig)</i> 66 kV/8 mA	<i>Pan (Film)</i> 66 kV/16 mA	<i>OFS</i> 77 kV/18.4 mA	<i>LH (Dig)</i> 84 kV/13 mA	<i>DVT</i> 110 kV/5.4 mA	<i>Picker CT</i> 130 kV/30 mA	<i>Picker CT</i> 130 kV/125 mA	<i>Siemens Ms-CT</i> 120 kV/42 mA
Orbita	0.0008	0.00155	0.0037	0.00355	0.0925	0.03275	0.187	0.4656
Cornea surface	0.0001	0.00024	0.00045	0.00101	0.0249	0.00664	0.02593	0.10131
Orbita, distal	0.00115	0.0025	0.00295	0.0036	0.1825	0.1218	0.76685	0.4736
Parotid gland	0.0137	0.0479	0.02385	0.0054	0.0915	0.1387	0.6521	0.4786
First molar maxilla	0.0015	0.00265	0.0033	0.0038	0.1975	0.41035	0.8709	0.444
Pharynx	0.02445	0.0387	0.0134	0.0018	0.148	0.3575	1.5616	0.4564
Bone mandibular angle	0.0079	0.01355	0.0141	0.00365	0.1445	0.4316	1.4761	0.45305
Cheek surface	0.00083	0.00199	0.00308	0.00086	0.0267	0.10192	0.22609	0.11184
Floor of the mouth, distal	0.0253	0.0203	0.0143	0.0029	0.1315	0.5965	1.2824	0.46105
Floor of the mouth, ventral	0.00415	0.00425	0.0067	0.0031	0.1375	0.5875	1.2074	0.3685
Chin surface	0.0002	0.00014	0.00085	0.0011	0.0161	0.10375	0.22743	0.03095

Pan, panoramic view, either digital (dig) or conventional (film); OFS, occipito-frontal scan; LH, lateral head film; DVT, digital volume tomography; CT, computed tomography, either Picker or Siemens Erlangen, Germany; Picker International Inc., Highland Heights, OH. The values in bold are the minimum and maximum doses for each technique

Before analysis, the TLDs were pre-heated for 10 min at 100 °C (“pre-tempered”), in order to delete the light signals depending on the ambient temperature. Directly afterwards the detectors were read out in a TLD reader TOLEDO 654 TLD ReaderT (Vinten Instruments Ltd, UK) under a 400 cm³ min⁻¹ nitrogen flux. The reading cycle with continuously increasing reading temperature was started at 240°C and stopped after 32 s (corresponding to about 280°C).

After analysis the TLDs were regenerated for 1 h at 400°C.

After multiplication of the energy dose values with organ weighting factors w_1 in accordance with the recommendations of the International Radiation Protection Commission (ICRP), effective doses E for the individual investigation could be estimated by summation of the organ doses determined in accordance with the formula:

$$E = w_1 \cdot H_1 + w_2 \cdot H_2 + \dots = \sum_T w_T \cdot H_T \quad (1)$$

where E = effective dose; w_T = weighting factors of the ICRP; H_T = mean organ doses weighted with an evaluation factor 1 for the radiation quality used.^{12,13}

This estimate is, however, incomplete, as the correct summation corresponding to the recommendations of the ICRP is carried out via 13 defined organs, most of which were not included in our investigation. However, in the present investigations the organ doses are near zero for most of the organs to consider, *e.g.* gonads, bladder, chest, digestive system, red bone marrow, and can therefore in this case be neglected.

Clinical samples

The clinical sample consisted of young cleft patients who were imaged as part of a routine interdisciplinary

orthodontic and surgical treatment planning at Heidelberg University Hospital (Department of Oral and Maxillofacial Surgery and Department of Orthodontics).

Case A demonstrates a unilateral complete cleft in a young girl on the left side. At the age of 8 months, cheiloplasty according to the method of Tennison and Randall was performed, at the age of 20 months operative palatoplasty according to the method of Veau and Axhausen was carried out. Imaging by means of DVT was used for assessment of quality and quantity valence of the tooth material in the context of therapy planning (osteoplasty and possibly (compensational) extraction).

Case B demonstrates a unilateral complete cleft in a young girl on the right side. Cheiloplasty (Tennison/Randall) was performed at the age of 6 months, operative palatoplasty at the age of 30 months. Also in this case was imaging by means of DVT carried out in order to assess the quality and quantity valence of the tooth material in the context of therapy planning (osteoplasty, mesiodens, possibly extraction).

Results

Weighted equivalent dose (Table 1)

The weighted equivalent doses for the digital panoramic view ranged from 0.0001 mSv (cornea) to 0.025 mSv (distal floor of the mouth) (Table 1). For the conventional variant, the calculated values were between 0.0001 mSv (chin) and 0.047 mSv (parotid gland). For the occipito-frontal scan, the weighted equivalent doses calculated were between 0.0004 mSv (cornea) and a 0.023 mSv (parotid gland).

The weighted doses from the investigation of the digital lateral head film were between 0.0008 mSv (minimum

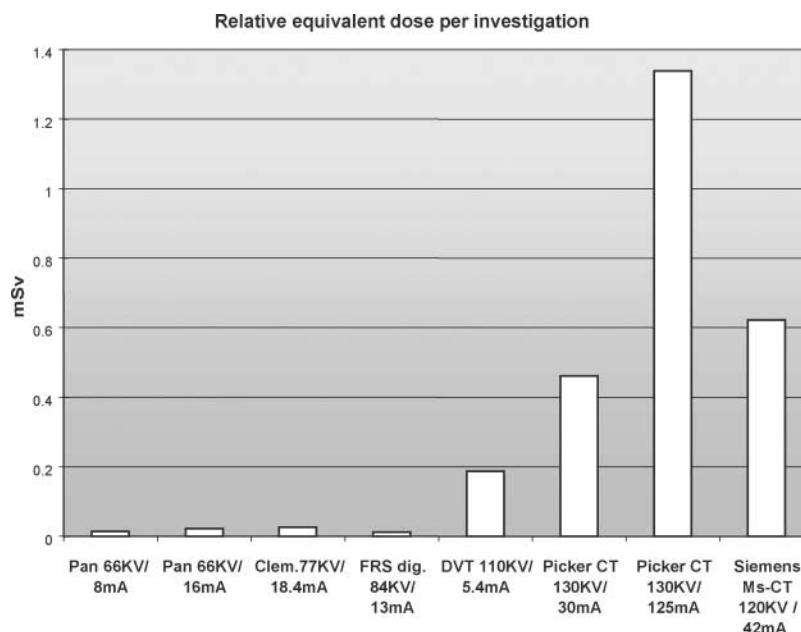


Figure 1 Graphic representation of the relative equivalent dose per investigation in mSv. OPG, orthopantomogram; OFS, occipito-frontal scan; LH, lateral head film; DVT, digital volume tomography; CT, computed tomography, either Picker or Siemens

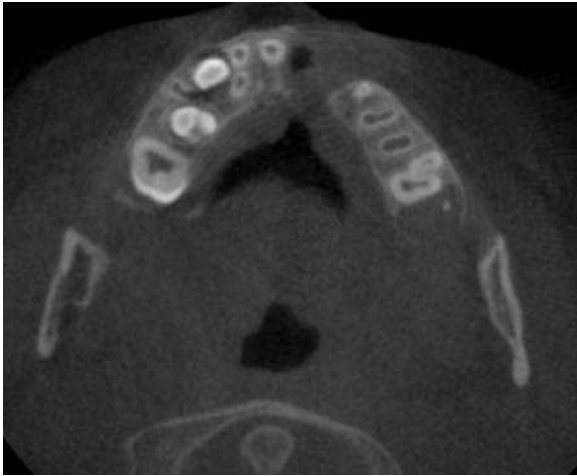


Figure 2 Patient A. Axial section at the level of the alveolar process of the maxilla with imaging of the cleft and the tooth constellation

value, cheek surface) and 0.0054 mSv (maximum value, parotid gland). The dose values of the DVT were between 0.016 mSv (minimum value, chin surface) and 0.197 mSv (maximum value, first molar maxilla). The reduced spiral protocol (45 mAs) showed values between 0.006 mSv (minimum value, cornea) and 0.597 mSv (maximum value, distal floor of the mouth) (130 kV, 33 mA, 1.5 s). In standard mode, the spiral investigation with the Picker CT (130 kV, 125 mA, 1.5 s) measured weighted dose values between 0.025 mSv (cornea) and 1.562 mSv (pharynx). The investigation with the Siemens CT device rendered doses between 0.03 mSv (minimum value, chin) and 0.47 mSv (maximum value, distal floor of the mouth).

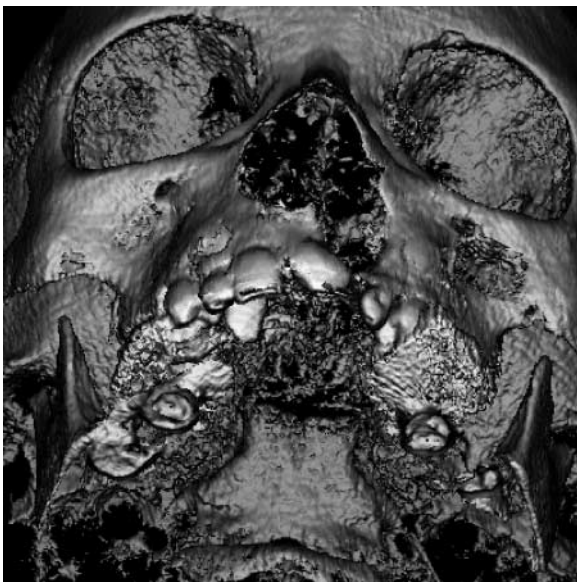


Figure 3 Patient A. Three-dimensional reconstruction with imaging of the cleft anatomy with good osseous reconstruction and slight reconstruction artefacts

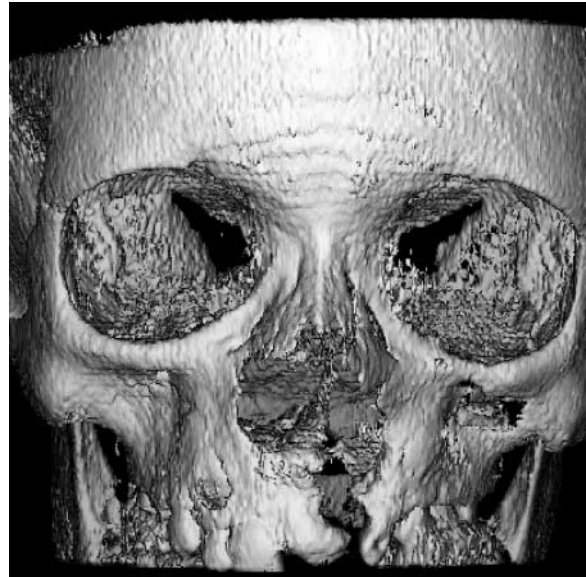

Figure 4 Patient A. Three-dimensional reconstruction with imaging of the facial bones and the palate

Relative equivalent dose per investigation (Figure 1)

For the digital panoramic device an effective investigation dose of 0.016 mSv was determined following the ICRP protocol.¹² The investigation dose of the conventional variant was calculated to have a value of 0.028 mSv. For the occipito-frontal scan and lateral head film effective investigation doses of 0.020 mSv and 0.008 mSv were calculated, respectively. The total average effective investigation dose of the DVT was 0.342 mSv.

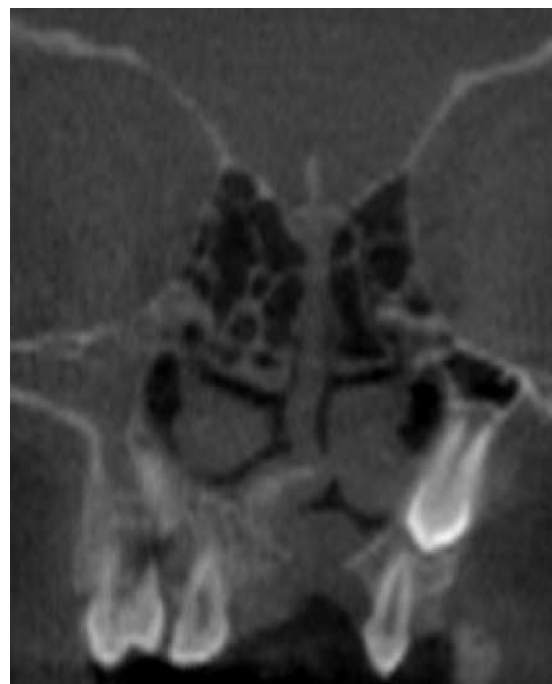

Figure 5 Patient A. Coronal reconstruction of the cleft with imaging of the tooth constellation

The investigation dose of the reduced spiral protocol of the Picker CT device was estimated to be 0.79 mSv by means of summation of the effective organ doses weighted corresponding to ICRP recommendations, but the dose for the same device in the conventional protocol was 2.27 mSv. The Siemens CT device in its test arrangement was estimated at 0.98 mSv (Figure 1).

Therefore the DVT dose is higher than the total dose per investigation in both digital and conventional panoramic equipment and above the occipito-frontal scan and the digital lateral head film. However, the values measured in the DVT scan were far less than the estimated total effective investigation dose in the standard mode of the helical scan in Picker CT and on the multislice Siemens CT. The radiation exposure during a DVT examination is even below that of a reduced-radiation CT protocol, like the one developed and published by Hassfeld *et al.*¹¹

Case A: On the basis of the DVT examination, insertion of tooth 12 was not performed (space for insertion, root diameter and length (size) of the tooth) and it was removed. In addition, 34 and 44 were extracted for compensation purposes. The DVT study provided axial (Figures 2–5), coronal and three-dimensional imaging which aided surgical treatment planning.

Case B: By means of DVT, the position of the mesiodens (Figures 6–10) could be determined precisely. In addition, the neighbouring teeth and the bone mass could be evaluated. Adequate planning of the operation could be carried out after a single investigation, due to the three-dimensional information. The three-dimensional bone mass at the floor of the nose and a single individual tooth could be visualized in detail in the DVT reconstruction.

Discussion

In recent years, the interest in rapidly obtaining digital tomographic information in all projection planes for visualizing structures in the oromaxillofacial region has greatly increased, especially with the development of new

surgical techniques.¹⁴ Since the 1980s, dental computer-supported tomography instruments have been developed continuously on an international scale.^{8–10} Almost all systems available today are based on the “cone beam” technique in which the objects detected in the path of the cone beam are converted mathematically into a digital image by means of algorithms.^{15–17} So far, this has only been possible in CT imaging, which was reserved for special situations because of the substantial radiation exposure with its deleterious consequences for the young patient’s body. In special investigations to appraise osseous structures, use of low-dose CT could also entail a maximum reduction of the radiation exposure by 76% without a loss of diagnostic accuracy.¹² According to our measurements, however, the radiation exposure in low-dose CT is greater than that in DVT.^{1,10} In view of this, the “smart beam” technique of the NEW TOM with a maximum of one seventh to one tenth of the CT dose in a conventional protocol with identical experimental design provides a way of utilizing DVT information with justifiable radiation risk more frequently, even in cleft patients.

Digital volume tomographic information can, in principle, also be achieved by means of conventional CT, but with a substantial radiation exposure. Especially in our interdisciplinary collaboration, questions with regard to the prognosis of individual teeth could be clarified with DVT imaging time and again when the imaging in conventional scans was unclear or incomplete. The image quality of DVT does not quite correspond to the usual quality of CT. This can be explained by the very much simpler construction (CCD chip, image amplifier) and the cone beam scanning technique. The superimposition of circular artefacts in the projection planes also results from this. However, with lower radiation exposure DVT furnishes information that is comparable with that of CT, especially in the imaging of bony or other structures of high contrast.³ DVT provides data for rapid radiological cranium diagnostics in cleft patients with metric precision in all spatial planes and the potential for high-resolution three-dimensional reconstruction.⁹ The clinical cases shown

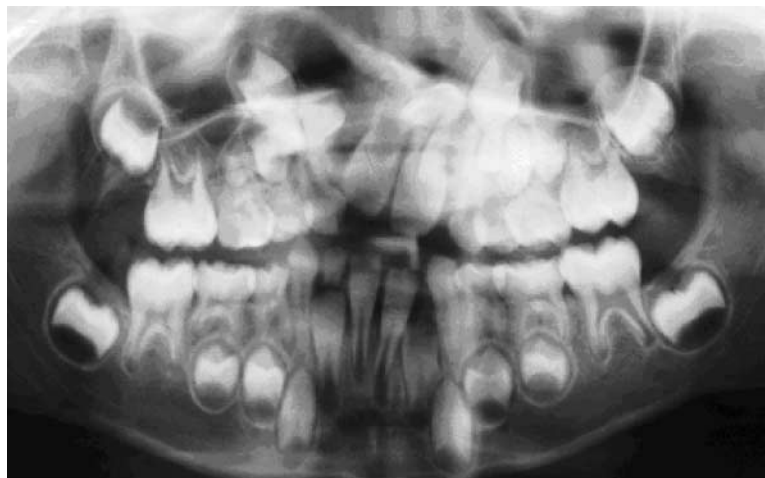

Figure 6 Patient B. Panoramic radiograph with blurred imaging of a mesiodens in the region of the cleft

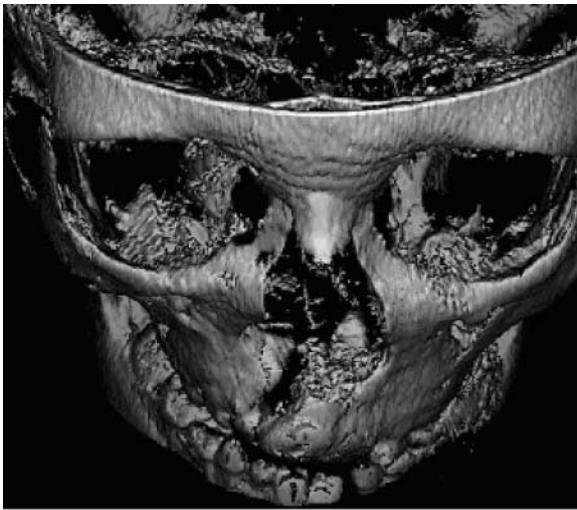


Figure 7 Patient B. Three-dimensional reconstruction with imaging of the facial bones and the mesiodens in the region of the cleft

illustrate the feasibility of reconstructing the cleft in any given spatial plane and 3D reconstruction from any given angle. The angle and distances can also be measured with the classical methods and complex extraction plans can be established in conjunction with the panoramic projection. In this way, pre-operative interdisciplinary treatment concepts can be ideally planned and pursued. Moreover, they can be re-evaluated visually and metrically at the end of treatment. This is not possible with any exactitude in conventional summation scans.

Our samples A and B demonstrate that the information obtained by DVT is superior to that obtained by conventional imaging (panoramic, lateral and frontal views) as regards decision for a treatment. For example, the panoramic view did not provide the information required on the mesiodens in question. In terms of radiation exposure (combined) both imaging techniques are almost equal.

The advantage of conventional imaging techniques can certainly be seen in the lower radiation exposure.

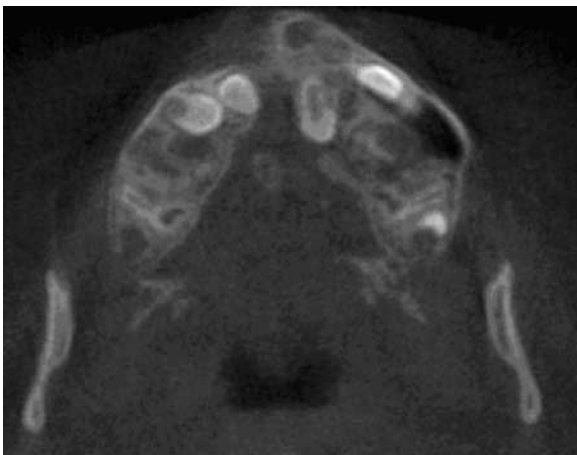


Figure 8 Patient B. Axial reconstruction of the cleft with imaging of the tooth constellation and the mesiodens in the region of the cleft

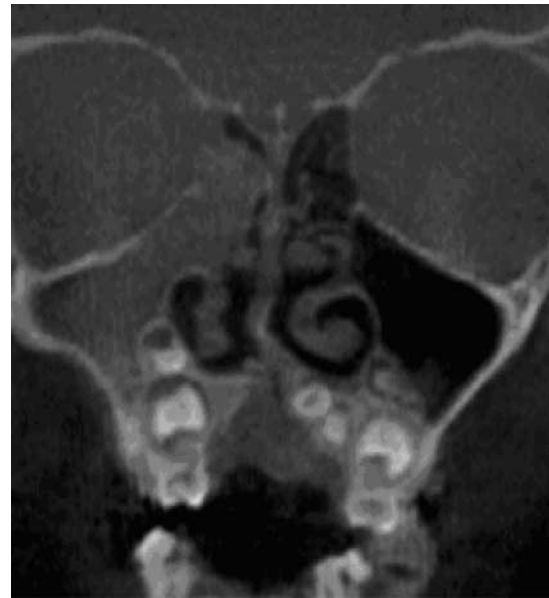

Figure 9 Patient B. Coronal reconstruction with imaging of the palate and the mesiodens

However, the reduced diagnostic information content of conventional imaging techniques in comparison with the three-dimensional techniques has to be taken into consideration.

The radiation exposure in conventional CT protocols should be confined to special individual cases. The DVT now represents a radiological method that can facilitate three-dimensional radiological diagnostics with significantly reduced radiation exposure in comparison with CT. The potentials of MRI also have to be taken into consideration; however, there is the known limited

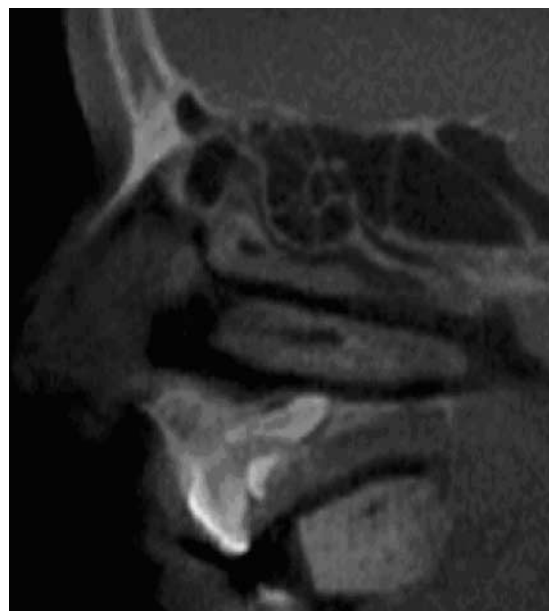

Figure 10 Patient B. Lateral reconstruction of the cleft with imaging of the positional relationship of the mesiodens to the palate

visualization of osseous tissue and the prolonged expenditure of time for this examination, which has to be considered as critical in young patients.

Conclusion

Due to its simple operation, the NEW TOM instrument can be integrated into practical routine work without difficulty. It is also used routinely for cleft diagnostics in

our hospital. Digital volume tomography can be regarded as equivalent to CT with regard to the diagnostic information provided in the high-contrast sector, but with very much shorter investigation time and very much lower purchase costs as well as lower radiation exposure. Although the radiation exposure is greater than that of conventional X-ray scanning instruments, *e.g.* digital panoramic X-rays, the diagnostic capacity of the latter is not remotely comparable with that of the NEW TOM instrument.

References

1. Bothe KJ, Becker H, Neukam FW. Die Computertomographie zur präoperativen Diagnostik bei extremer Alveolarfortsatzatrophie. *Jahrbuch für orale Implantologie*. Berlin: Quintessenz; 1993, pp. 105–109.
2. Fuhrmann R, Klein HM, Wehrbein H, Günther RW, Dietrich P. Hochauflösende Computertomographie fazialer und oraler Knochen-dehiszenzen. *Dtsch Zahnärztl Z* 1993; **48**: 242–246.
3. Ziegler CM, Woertche R, Brief J, Hassfeld S. Clinical indications for digital volume tomography in oral and maxillofacial surgery. *Dentomaxillofac Radiol* 2002; **31**: 126–130.
4. Tai CC, Sutherland IS, McFadden L. Prospective analysis of secondary alveolar bone grafting using computed tomography. *J Oral Maxillofac Surg* 2000; **58**: 1241–1250.
5. Van der Meij AJ, Baart JA, Prahl-Andersen B, Valk J, Kostense PJ, Tuinzing DB. Bone volume after secondary bone grafting in unilateral and bilateral clefts determined by computed tomography scans. *Oral Surg Oral Med Oral Pathol Oral Radiol Endod* 2001; **92**: 136–141.
6. Jia Y, Fu M, Ma L. The comparison of two-dimensional and three-dimensional methods in the evaluation of the secondary alveolar bone grafting. *Zhonghua Kou Qiang Yi Xue Za Zhi* 2002; **37**: 194–196.
7. Dado DV, Rosenstein SW, Alder ME, Kernahan DA. Long-term assessment of early alveolar bone grafts using three-dimensional computer-assisted tomography: a pilot study. *Plast Reconstr Surg* 1997; **99**: 1840–1845.
8. Arai Y, Tammissalo E, Iwai K, Hashimoto K, Shinoda K. Development of a compact computed tomographic apparatus for dental use. *Dentomaxillofac Radiol* 1999; **4**: 245–248.
9. Möbes O, Becker J, Pawelzik J, Jacobs K. Anwendungsmöglichkeiten der Digitalen Volumen-Tomographie in der implantologischen Diagnostik. *Zahnärztl Implantol* 1999; **15**: 229–233.
10. Siwerdsen JH, Jaffray DA. Cone-beam computed tomography with a flat-panel imager. *Med Phys* 1999; **26**: 2635–2647.
11. Hassfeld S, Streib S, Stahl H, Stratmann U, Fehrentz D, Zöllner J. Low-dose-Computertomographie des Kieferknochens in der präimplantologischen Diagnostik. *Mund Kiefer Gesichtschir* 1998; **2**: 188–193.
12. ICRP Publication 60, *Recommendations of the International Commission on Radiological Protection 1990*. Oxford: Pergamon Press; 1991.
13. Drexler G, Panzer W. Dosimetrische Kenngrößen, Methodik der Dosiermittlung, Anwendbarkeit und Grenzen des Konzepts der Effektivdosis. In: Bundesministerium für Umwelt, Naturschutz und Reaktorsicherheit, (eds). *Veröffentlichungen der Strahlenschutzkommission Band 30, Strahlenexposition in der medizinischen Diagnostik*. Stuttgart, Jena, New York: G. Fischer Verlag; 1995, pp. 29–49.
14. Solar P, Gahleitner A. Dental CT in the planning of surgical procedures. *Radiologe* 1999; **39**: 1051–1063.
15. Tam KC, Samarasekera S, Sauer F. Exact cone beam CT with a spiral scan. *Phys Med Biol* 1998; **43**: 1015–1024.
16. Bianchi SD, Lojaco A. 2D and 3D images generated by cone beam computed tomography (CBCT) for dentomaxillofacial investigations. In: Lemke HU, Vannier MV, Inamura K, Farman AG, (eds). *CARS '98 - Proceedings of the 12th International Symposium and Exhibition: Computer Assisted Radiology and Surgery*. Amsterdam: Elsevier; 1998, pp. 792–797.
17. Mozzo P, Procacci C, Tacconi A, Tiazzi Martini P, Bergamo Andreis IA. A new volumetric CT machine for dental imaging based on the cone-beam technique: preliminary results. *Eur Radiol* 1998; **8**: 1558–1564.